Sonographic Detection of Extracapsular Extension in Papillary Thyroid Cancer

Aya Kamaya, MD, Ali M. Tahvildari, MD, Bhavik N. Patel, MD, Juergen K. Willmann, MD, R. Brooke Jeffrey, MD, Terry S. Desser, MD

Objectives—To identify and evaluate sonographic features suggestive of extracapsular extension in papillary thyroid cancer.

Methods—Three board-certified radiologists blinded to the final pathologic tumor stage reviewed sonograms of pathologically proven cases of papillary thyroid cancer for the presence of extracapsular extension. The radiologists evaluated the following features: capsular abutment, bulging of the normal thyroid contour, loss of the echogenic capsule, and vascularity extending beyond the capsule.

Results—A total of 129 cases of pathologically proven thyroid cancer were identified. Of these, 51 were excluded because of lack of preoperative sonography, and 16 were excluded because of pathologic findings showing anaplastic carcinoma, follicular carcinoma, or microcarcinoma (<10 mm). The final analysis group consisted of 62 patients with papillary thyroid carcinoma, 16 of whom had pathologically proven extracapsular extension. The presence of capsular abutment had 100% sensitivity for detection of extracapsular extension. Conversely, lack of capsular abutment had a 100% negative predictive value (NPV) for excluding extracapsular extension. Contour bulging had 88% sensitivity for detection of extracapsular extension and when absent had an 87% NPV. Loss of the echogenic capsule was the best predictor of the presence of extracapsular extension, with an odds ratio of 10.23 ($P = .034$). This sonographic finding had 75% sensitivity, 65% specificity, and an 88% NPV. Vascularity beyond the capsule had 89% specificity but sensitivity of only 25%.

Conclusions—Sonographic features of capsular abutment, contour bulging, and loss of the echogenic thyroid capsule have excellent predictive value for excluding or detecting extracapsular extension and may help in biopsy selection, surgical planning, and treatment of patients with papillary thyroid cancer.

Key Words—capsular invasion; extracapsular extension; extrathyroidal extension; head and neck ultrasound; papillary thyroid cancer

Received February 3, 2015, from the Department of Radiology, Stanford University Medical Center, Stanford, California USA (A.K., J.K.W., R.B.J., T.S.D.); VA Palo Alto Health Care System, Palo Alto, California USA (A.M.T.); and Department of Radiology, Duke University, Durham, North Carolina USA (B.N.P.). Revision requested February 16, 2015. Revised manuscript accepted for publication March 17, 2015. We thank Pam Desmond for statistical analysis, Jeslyn A. Rumbold for assistance with manuscript preparation, and John Sunwoo, MD, for head and neck surgical advice. This material was presented at the American Roentgen Ray Society Annual Meeting; May 4–9, 2014; San Diego, California.

Address correspondence to Aya Kamaya, MD, Department of Radiology, Stanford University Medical Center, 300 Pasteur Dr, H1307, Stanford, CA 94305 USA.

E-mail: kamaya@stanford.edu

Abbreviations

CI, confidence interval; NPV, negative predictive value; PPV, positive predictive value

doi:10.7863/ultra.15.02006

The prognosis for differentiated thyroid cancer is generally excellent, with 99% survival at 20 years after surgery.[1,2] The risk of death in thyroid cancer increases, however, when extracapsular extension of a tumor is identified at surgery, decreasing the 10-year survival from 99.3% to 63%.[3] Although differentiated thyroid cancer is rarely lethal, morbidity from local recurrence is not insubstantial, with complications ranging from difficulty swallowing to tracheal invasion or recurrent laryngeal nerve invasion. The incidence of extracapsular extension of a tumor is estimated to range between 5% and 34% of well-differentiated thyroid cancers.

The presence of extracapsular extension has been found to increase the risk of recurrence 2-fold as well as the risk of death.[3–5] The degree to which extracapsular extension is present determines tumor staging in the TNM staging classification: T3 lesions have minimal extrathyroidal extension (extension to sternothyroid muscle or perithyroid soft tissues), and T4a disease includes tumors that extend beyond the capsule to invade subcutaneous soft tissues, the larynx, the trachea, the esophagus, and the recurrent laryngeal nerve.[6]

The presence of extracapsular extension of a tumor affects the surgical approach and increases the risk of incomplete surgical excision, which in turn is associated with higher morbidity and mortality.[7,8] Patients with T3 or T4 primary tumors will often undergo prophylactic central compartment neck dissection, as outlined in the American Thyroid Association guidelines.[9] In addition, if anterior extracapsular extension is suspected or confirmed, at our institution, the adjacent strap muscles may be resected as part of the surgical specimen.

Although extracapsular extension of a tumor carries important prognostic implications, to date, the sonographic prediction of extracapsular extension has not been extensively studied, and there are no established sonographic criteria for its prediction.[10,11] Preoperative sonography and lymph node mapping in patients pathologically confirmed to have thyroid malignancy are recommended by the American Thyroid Association to determine the need for further preoperative imaging. However, sonographic findings of extracapsular extension are not clearly delineated in this recommendation.[12] Currently, extracapsular extension is often diagnosed pathologically rather than radiographically. The purpose of our study was to evaluate pathologically proven thyroid cancers with and without extracapsular extension of the tumors and to determine which sonographic findings may be predictive of extracapsular extension.

Materials and Methods

Institutional Review Board approval and a consent waiver were obtained before the retrospective retrieval of all thyroidectomy pathologic specimens in the pathology database at our institution between 2002 and 2012. Clinical information, including age, sex, and pathologic findings at the time of surgical resection, were obtained through review of electronic medical records. Patients with a pathologic diagnosis of thyroid cancer were selected for review. Patients who did not have sonography before resection were excluded. In addition, patients with a diagnosis of anaplastic carcinoma, follicular carcinoma, or microcarcinoma (papillary cancer <10 mm) were excluded for the following reasons: anaplastic carcinomas by definition are T4 cancers at the time of diagnosis and typically are not surgical candidates; follicular carcinomas may only be diagnosed by complete surgical excision, and sonographic assessment is therefore often of limited utility; and microcarcinomas are typically incidental findings or may be sonographically occult, and the utility of surgical resection in these patients is not universally accepted[13]; moreover, the small size of microcarcinomas in a retrospective study may potentially lead to errors in colocation with pathologic findings.

All patients underwent sonography with an ACUSON Sequoia 512 ultrasound machine (Siemens Medical Solutions, Mountain View, CA) or a LOGIQ E9 ultrasound machine (GE Healthcare, Waukesha, WI) as part of their thyroid nodule evaluation, either for preoperative imaging or selection for fine-needle aspiration. Sonograms at our institution were obtained by a trained sonographer and checked by a board-certified radiologist at the time of scanning, with the option of obtaining additional images at that time. As part of our diagnostic sonographic examination protocol, patients were placed in the supine position with the neck slightly hyperextended. A high-frequency linear transducer (12–18 MHz) with harmonic imaging was used to image the neck in both transverse and longitudinal views using grayscale imaging with color or power Doppler imaging, or both.

Two board-certified radiologists (A.K. and A.T.) with expertise in thyroid imaging, who did not participate in the blinded review, created a training set of example cases in a PowerPoint presentation (Microsoft Corporation, Redmond, WA) with 3 examples of each feature and descriptions of the sonographic findings to familiarize the blinded reviewers with sonographic features. The cases for the training set were obtained outside the retrospective review.

Sonograms were retrospectively reviewed by 3 experienced board-certified radiologists (T.S.D., R.B.J., and J.K.W.) with expertise in sonography and thyroid imaging (25, >25, and 14 years of experience, respectively), who were blinded to the findings of extracapsular extension at resection. Images were retrospectively reviewed by each observer independently on a Centricity picture archiving and communication system workstation (GE Healthcare) with Barco color monitors (Barco Inc, Kortrijk, Belgium) with either 2-megapixel 1600 × 1200 or 2.3-megapixel 1920 × 1200 resolution. The radiologists evaluated the following sonographic features: capsular abutment by the nodule (Figures 1–3), bulging of the normal thyroid con-

tour (Figure 4), loss of the echogenic capsule (Figure 3), and vascularity extending beyond the nodule (Figure 5). When interpretation differed, the majority opinion was used.

Capsular abutment was evaluated as "present" or "not present" by each observer when the thyroid nodule was seen to abut the margin of the thyroid capsule on imaging. Note was made of whether abutment occurred with the anterior capsule, posterior capsule, or both. Contour bulging was identified when the contour of the anterior capsule was bulged outward by the thyroid nodule beyond the expected normal thyroid margin and recorded as "yes" or "no" by each radiologist. Loss of the echogenic capsule was assessed as "present" if the normally echogenic rim of the thyroid gland was not sonographically detectable and presumed to be obscured by the thyroid nodule, and "not

Figure 1. Sonograms from a 50-year-old woman with papillary cancer in the left thyroid gland. **A**, Transverse view. **B**, Longitudinal view. The nodule (green arrows) does not abut the capsule (orange arrows). No extracapsular extension was seen on pathologic examination.

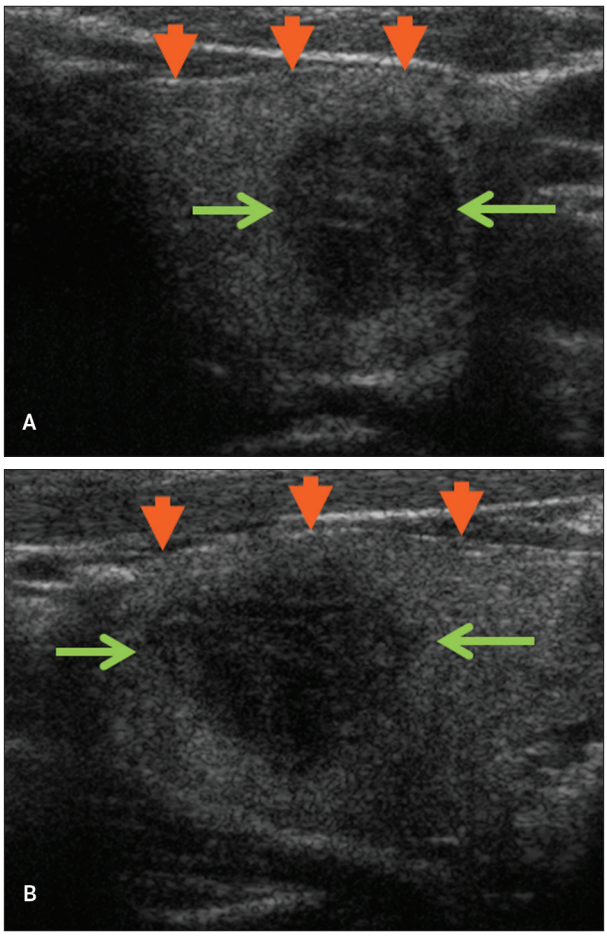

Figure 2. Sonogram from a 21-year-old woman with papillary cancer (green arrows). The nodule abuts more than 25% of the capsule, but the echogenic capsule is well visualized (orange arrows). No extracapsular extension was seen on pathologic examination.

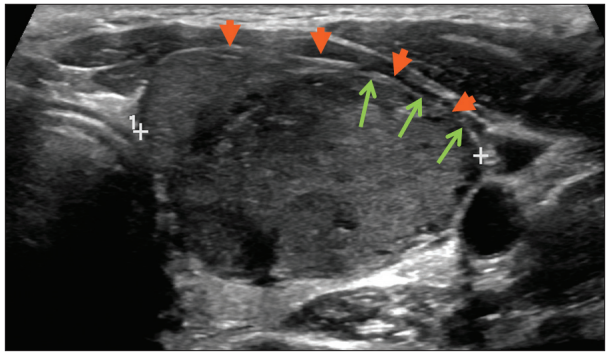

Figure 3. Sonograms from an 80-year-old woman with papillary cancer and extracapsular extension. **A**, Transverse view of the left thyroid showing the nodule abutting the capsule, with loss of the capsule along the anterior margin (green arrows). A portion of the anterior echogenic capsule (orange arrows) is still visible. **B**, Longitudinal view showing that the superior portion of the anterior capsule is not visible (green arrows). Portions of the capsule are vaguely shown along the inferior margin (orange arrows).

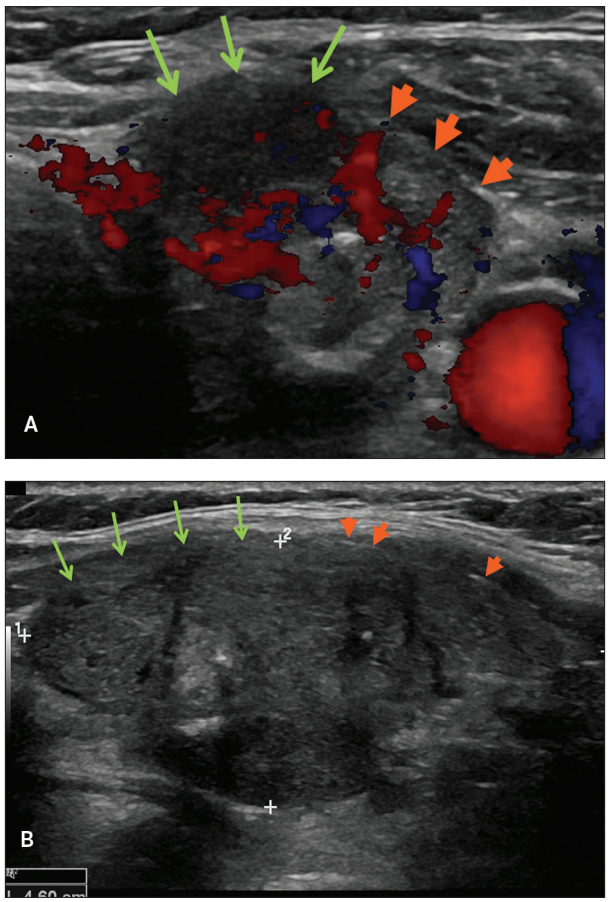

present" if the echogenic capsule was still visible in its entirety. Finally, vascularity beyond the nodule was assessed as "present" if vessels extending to or from the nodule were seen beyond the capsule on either color or power Doppler images.

Results

Between 2002 and 2012, 1036 thyroidectomy specimens were evaluated at our institution. Of these, 129 cases of pathologically proven thyroid cancer were identified; 51 were excluded because of lack of preoperative sonography, and 16 were excluded because of pathologic findings showing anaplastic carcinoma, follicular carcinoma, or microcarcinoma. The final analysis group consisted of 62 patients with papillary thyroid cancer, 16 (26%) of whom had pathologically proven extracapsular extension, and 46 did not. The average age of the final group was 48.9 years (40 female and 22 male). Of the 16 patients with extracapsular extension (average age, 59.2 years; 9 female and 7 male), 13 had T3 disease, and 3 had T4 disease.

Based on the majority consensus, the presence of capsular abutment was seen in all nodules with extracapsular extension, resulting in 100% sensitivity (95% confidence interval [CI], 79.4%–100%). Conversely, absence of capsule abutment had a 100% negative predictive value (NPV) for excluding extracapsular extension (95% CI, 54.1%–100%), although the specificity and positive predictive value (PPV) were only 13% (95% CI, 4.9%–26.3%) and 29% (17.3%–42.2%), respectively.

Contour bulging had 88% sensitivity (95% CI, 61.7%–98.4%) for detection of extracapsular extension and when absent had an 87% NPV (95% CI, 59.5%–98.3%). The specificity for extracapsular extension with contour bulging was 28% (95% CI, 16.0%–43.5%), with a 30% PPV (95% CI, 17.3%–44.9%).

Vascularity beyond the capsule had 89% specificity (95% CI, 76.4%–96.4%) but was not a sensitive finding, at only 25% (95% CI, 7.3%–52.4%). The PPV and NPV of vascularity beyond the capsule were 44.4% (95% CI, 13.7%–78.8%) and 77.4% (95% CI, 6.8%–87.7%), respectively.

Loss of the echogenic capsule had 75% sensitivity (95% CI, 47.6%–92.7%), 65% specificity (95% CI, 49.8%–78.6%), a 42.9% PPV (95% CI, 24.5%–62.8%), and an

Figure 4. Sonogram from a 61-year-old woman with papillary cancer and extracapsular extension. Longitudinal view of the left thyroid. The nodule (calipers) bulges the anterior contour (green arrows) of the thyroid, where the echogenic capsule is lost. In the area not involved by the nodule, the echogenic capsule is preserved (orange arrows).

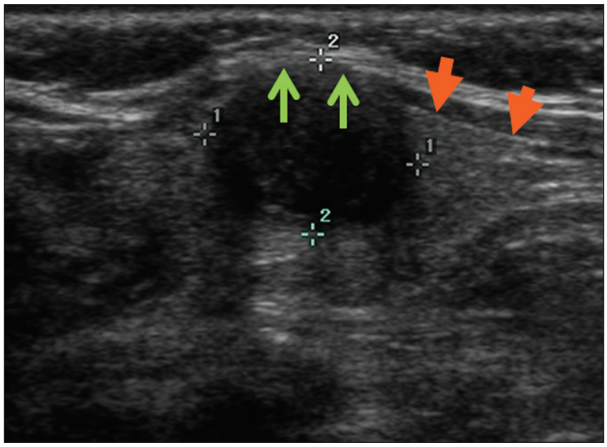

Figure 5. Sonograms from a 52-year-old woman with papillary cancer and extracapsular extension. **A**, Longitudinal color Doppler image showing vascularity (green arrow) extending beyond the capsule. **B**, Longitudinal grayscale image in the same location showing margins of the nodule (green arrows) with loss of the echogenic capsule. The echogenic capsule (orange arrows) is shown superiorly in the area not abutting the thyroid nodule.

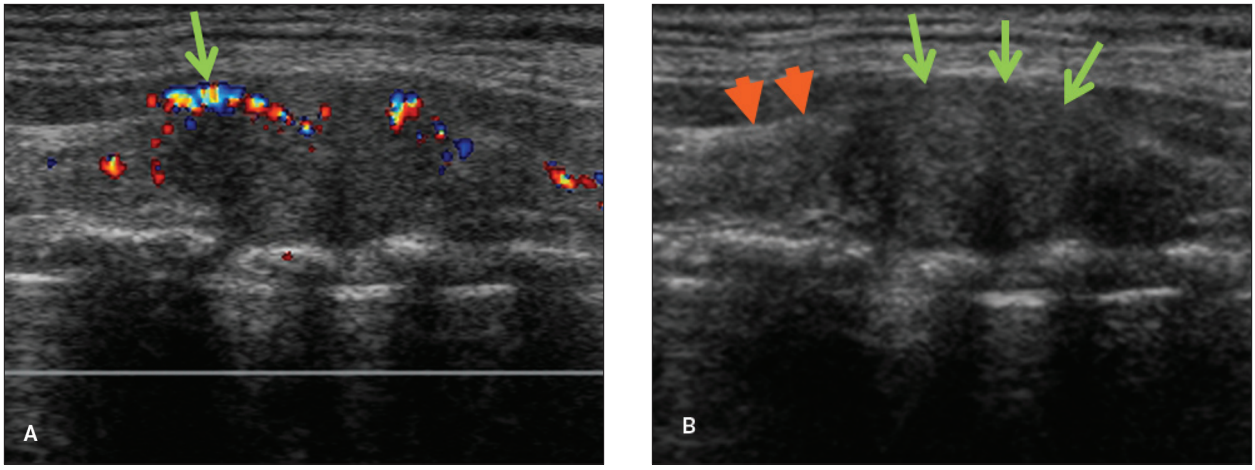

88% NPV (95% CI, 72.5%–96.7%). However, in a logistic regression analysis, loss of the echogenic capsule was the best sonographic predictor of extracapsular extension, with an odds ratio of 10.23 ($P = .034$).

When 2 or more features were present, the sensitivity for detection of extracapsular extension was 100%, with specificity of 26%, a PPV of 32%, and an NPV of 100%. When 3 or more features were present, the sensitivity was 63%, with specificity of 70%, a PPV of 42%, and an NPV of 84%. When all 4 features were present, the sensitivity was 25%, with specificity of 93%, a PPV of 57%, and an NPV of 78%.

Discussion

We found several sonographic features that were helpful in the assessment of extracapsular extension of papillary thyroid carcinoma. When capsular abutment was not present, extracapsular extension was virtually excluded. Conversely, when a papillary carcinoma caused contour bulging and effacement of the echogenic thyroid capsule, extracapsular extension of the tumor was suspected. Although we were not able to find a single sonographic feature that had both high sensitivity and a high PPV, when combinations were studied, the greater the number of features present, the higher the PPV. Thus, whereas no single sonographic feature was highly predictive of extracapsular extension, careful evaluation of the capsule with these sonographic features in mind may help in biopsy selection, surgical planning, and treatment of patients with papillary cancer.

Several older studies evaluated the preoperative characterization of extracapsular extension, with mixed findings. Shimamoto et al[14] studied sonographic prediction in staging of papillary cancer and found that the sensitivity of sonography for detection of extracapsular extension of a tumor into the prethyroidal muscles and sternocleidomastoid was 77.8%, but the sensitivity values for invasion into the trachea and the esophagus were only 49% and 28.6%, respectively. That study, from 1998, used lower-frequency transducers (7.5–10 MHz) than our study (12–18 MHz) and was performed before the widespread use of harmonic imaging, compound imaging, and other sonographic techniques that have improved the resolution of sonography in current practice. A different study by Yamamura et al[15] from 2002 had much better results using preoperative sonography for detection of cancer invasion of the airways and found that sonography had an 83.3% accuracy rate, which was better than magnetic resonance imaging or computed tomography.

A few more-recent studies evaluated preoperative prediction of extracapsular extension with better results. In a study of 181 patients, Kwak et al[16] found 65.2% sensitivity and 81.8% specificity for sonography using measurement of the percentage of contact of the nodule with the thyroid capsule. However, in that study, all cases were microcarcinomas, for which sonographic findings and the prognosis may not be applicable to all papillary cancers and for which surgical treatment remains somewhat controversial.[13] A recent study by Lee et al[10] had results that were similar to ours: abutment (percentage of the nodule perimeter abutting the capsule) and capsular protrusion (defined as loss of the perithyroidal echogenic line) were useful for predicting extracapsular extension. However, in their study, all images were obtained by radiologists who were aware of the confirmed diagnosis of thyroid carcinoma, rather than by sonographers performing routine diagnostic scans of the entire thyroid, as in our study. We think that our study more closely reflects standard practice in the United States and confirms that these sonographic findings can indeed be assessed even when the diagnosis of thyroid cancer is not known and images are obtained by a trained sonographer and interpreted by a radiologist.

There were several limitations to our study. First, this study was retrospective, with a relatively small patient cohort. This limitation was due to the fact that both sonographic assessment and pathologic surgical specimens were required. Second, the full extent of the invasion of adjacent structures was not assessed on our sonographic examinations. We also did not attempt to differentiate between T3 and T4 lesions. Although we acknowledge that it is an important distinction, the focus of our study was to determine whether extracapsular extension was present. Future studies of sonographic assessment are needed to delineate T3 from T4 lesions. Third, since this study was a retrospective review, detailed evaluation of the capsule was not performed prospectively in each case; therefore, there was a possibility that the entire capsule was not fully imaged or viewed during review. We anticipate that with improved sonographic technology using higher-frequency and higher-resolution transducers, focused attention of the capsule could be prospectively performed and the sensitivity for extracapsular extension improved. Fourth, we excluded microcarcinomas in our study, for which treatment remains controversial. Some authors suggest that microcarcinomas may be safely observed,[13,17] and a recent article by Chéreau et al[18] suggested that microcarcinomas with extracapsular extension have outcomes that are similar to those of T2 disease. Although we think this topic requires further investigation, because of the retrospective nature of our study we

excluded microcarcinomas to accurately correlate pathologic results with sonographic findings. Fifth, we found the anterior capsule was much better visualized than the posterior capsule. This finding relates to the inherent nature of sonography, in which detail of deeper structures is lower in resolution compared to more superficial structures. However, since invasion of the strap muscles overlying the thyroid accounts for most patients with extracapsular extension (62%), it is evaluation of the anterior capsule that is critical.[11]

The American Thyroid Association recommends sonographic evaluation of the primary thyroid tumor and lymph node mapping in patients who have proven papillary thyroid cancer.[12] However, we encourage focused high-resolution sonographic evaluation of the thyroid capsule in examinations of all unknown thyroid nodules. The sonographic features we studied may help identify suspicious features that can in turn help guide biopsy decisions. Identification of features can be facilitated by placing the focal zone at the level of the capsule, using higher-frequency linear transducers (ie, 18 MHz) for anterior capsule evaluation, and evaluating both the anterior and posterior thyroid capsules. Future prospective studies may help determine the benefit of dedicated capsule evaluation with a detailed sonographic examination.

In conclusion, we found several sonographic features that are helpful in evaluations for extracapsular extension of papillary cancer. Given that the presence of extracapsular extension has important prognostic and staging implications, its accurate preoperative identification may potentially help guide the surgical approach and subsequent clinical management.

References

1. Hay ID, Bergstralh EJ, Goellner JR, Ebersold JR, Grant CS. Predicting outcome in papillary thyroid carcinoma: development of a reliable prognostic scoring system in a cohort of 1779 patients surgically treated at one institution during 1940 through 1989. *Surgery* 1993; 114:1050–1058.
2. Frates MC, Benson CB, Charboneau JW, et al. Management of thyroid nodules detected at US: Society of Radiologists in Ultrasound consensus conference statement. *Radiology* 2005; 237:794–800.
3. Ortiz S, Rodriguez JM, Soria T, et al. Extrathyroid spread in papillary carcinoma of the thyroid: clinicopathological and prognostic study. *Otolaryngol Head Neck Surg* 2001; 124:261–265.
4. Andersen PE, Kinsella J, Loree TR, Shaha AR, Shah JP. Differentiated carcinoma of the thyroid with extrathyroidal extension. *Am J Surg* 1995; 170:467–470.
5. Siegel R, Ma J, Zou Z, Jemal A. Cancer statistics, 2014. *CA Cancer J Clin* 2014; 64:9–29.
6. Edge S, Byrd DR; American Joint Committee on Cancer; American Cancer Society. *AJCC Cancer Staging Handbook: From the AJCC Cancer Staging Manual.* 7th ed. New York, NY: Springer; 2010.
7. Morton RP, Ahmad Z. Thyroid cancer invasion of neck structures: epidemiology, evaluation, staging and management. *Curr Opin Otolaryngol Head Neck Surg* 2007; 15:89–94.
8. Shah JP, Loree TR, Dharker D, Strong EW, Begg C, Vlamis V. Prognostic factors in differentiated carcinoma of the thyroid gland. *Am J Surg* 1992; 164:658–661.
9. Cooper DS, Doherty GM, Haugen BR, et al. Revised American Thyroid Association management guidelines for patients with thyroid nodules and differentiated thyroid cancer. *Thyroid* 2009; 19:1167–1214.
10. Lee CY, Kim SJ, Ko KR, Chung KW, Lee JH. Predictive factors for extrathyroidal extension of papillary thyroid carcinoma based on preoperative sonography. *J Ultrasound Med* 2014; 33:231–238.
11. Hu A, Clark J, Payne RJ, Eski S, Walfish PG, Freeman JL. Extrathyroidal extension in well-differentiated thyroid cancer: macroscopic vs microscopic as a predictor of outcome. *Arch Otolaryngol Head Neck Surg* 2007; 133:644–649.
12. Yeh MW, Bauer AJ, Bernet VA, et al; American Thyroid Association Surgical Affairs Committee Writing Task Force. American Thyroid Association statement on preoperative imaging for thyroid cancer surgery. *Thyroid* 2015; 25:3–14.
13. Ito Y, Miyauchi A, Inoue H, et al. An observational trial for papillary thyroid microcarcinoma in Japanese patients. *World J Surg* 2010; 34:28–35.
14. Shimamoto K, Satake H, Sawaki A, Ishigaki T, Funahashi H, Imai T. Preoperative staging of thyroid papillary carcinoma with ultrasonography. *Eur J Radiol* 1998; 29:4–10.
15. Yamamura N, Fukushima S, Nakao K, et al. Relation between ultrasonographic and histologic findings of tracheal invasion by differentiated thyroid cancer. *World J Surg* 2002; 26:1071–1073.
16. Kwak JY, Kim EK, Youk JH, et al. Extrathyroid extension of well-differentiated papillary thyroid microcarcinoma on US. *Thyroid* 2008; 18:609–614.
17. Moon HJ, Lee HS, Kim EK, et al. Thyroid nodules ≤5 mm on ultrasonography: are they "leave me alone" lesions? *Endocrine* 2015; 49(3): 735-44.
18. Chéreau N, Buffet C, Trésallet C, et al. Does extracapsular extension impact the prognosis of papillary thyroid microcarcinoma? *Ann Surg Oncol* 2014; 21:1659–1664.